

## Analysis of D-dimer Levels in Deep Vein Thrombosis Patients

**Anton Triyadi, Rachmawati A. Muhiddin, Agus Alim Abdullah**

Department of Clinical Pathology, Faculty of Medicine, Hasanuddin University/Dr. Wahidin Sudirohusodo Hospital, Makassar, Indonesia.  
E-mail: [anton.triyadi@gmail.com](mailto:anton.triyadi@gmail.com)

### ABSTRACT

It is reported the incidence of DVT is approximately 84 cases per 100,000 each year, with 30-50% of untreated DVT are at risk for pulmonary embolism, causing a 12% increase in mortality rate. An accurate and rapid diagnosis of DVT is needed to minimize the risk of complications and prevent unnecessary anticoagulant therapy without waiting for the results of a diagnostic examination using ultrasound. This study aimed to determine the diagnostic value of plasma D-dimer levels on Doppler ultrasound for DVT diagnosis to help clinicians to select a rapid and accurate diagnostic test for DVT diagnosis. This research was a retrospective study using data from medical records and performed at the Medical Record Installation of Dr. Wahidin Sudirohusodo Hospital, Makassar, by taking data on patients with DVT along with the results of D-dimer and Doppler ultrasound from January to December 2018. D-dimer levels were measured using an immunoturbidimetric method with a reference value of  $<0.5 \mu\text{g/mL}$ . A total of 33 samples were obtained with a mean of D-dimer value was higher in positive Doppler (5.29) compared to negative (2.31), although not statistically significant ( $p > 0.05$ ). Also, the mean of Wells score was higher in positive Doppler (4.74) compared to negative (4.17), although not statistically significant ( $p > 0.05$ ). The diagnostic values of D-dimer were as follows: sensitivity of 92.6%, specificity of 33.3%, positive predictive value of 86.2%, negative predictive value of 50.0%, and accuracy of 81.8%. D-dimer test can be used both for screening and diagnostic tests with cut-off value  $\geq 2 \mu\text{g/mL}$ .

**Keywords:** Deep vein thrombosis, D-dimer, Doppler ultrasound

### INTRODUCTION

Deep Vein Thrombosis (DVT) is a condition that results from the formation of blood clots in deep veins and most frequently found in veins of the lower limbs such as the popliteal vein, the superficial femoral vein, and the iliofemoral venous segment.<sup>1</sup> DVT can result in high morbidity and mortality if it is not early diagnosed and treated on time.<sup>2,3</sup> DVT is a health problem with incidents of approximately 84 cases per 100,000 each year, with 30-50% of cases of untreated DVT are at risk of pulmonary embolism, causing a 12% increase in mortality rate. Therefore, it is crucial to be immediately treated.<sup>4</sup>

A diagnosis of DVT, which is merely based on clinical signs and symptoms, is less accurate. Several complaints, such as classic symptoms of pain, swelling, and tenderness, are experienced by most patients. Thus, an objective examination is needed to diagnose DVT. The diagnostic approach uses a scoring system of Wells score for a clinical disease, which is confirmed by ultrasonography (ultrasound) and laboratory tests. The gold standard for diagnosis of DVT is venography. However, it is highly invasive, expensive, and not widely available in every hospital.<sup>5,6</sup>

It is advisable to screen patients who are at high risk for DVT, including those with well scores. Interpretation (probability) of DVT is determined based on the number of scores obtained. A score of less than 1 shows a low probability, a score of 1-2 shows a moderate probability, and a score of 3 or more shows a high probability.<sup>7</sup>

Doppler ultrasonography is a supporting examination for the diagnosis of non-invasive DVT, which can be used to estimate the blood flow through blood vessels by reflecting high-frequency sound waves from circulating red blood cells. This examination has 97% sensitivity and 95% specificity to diagnose DVT. Abnormal results can be used to diagnose DVT; however, normal results must be repeated in the following week.<sup>3</sup> Diagnosis using ultrasound is very important, despite several limitations. Doppler ultrasound requires interpretation from a radiologist and has poor sensitivity to detect venous thrombosis in the calf. In addition, serial testing is frequently needed when the negative results of the initial examination are obtained.<sup>8</sup>

D-dimers are fibrin degradation products found in the blood after degradation of thrombus by

thrombin, coagulation factors XIIIa, and fibrinolysin. D-dimer expression levels can represent coagulation activity, and the fibrinolytic system can be used to support the diagnosis of DVT. Measurement of D-dimer levels has been widely studied as an additional test for the determination of DVT. D-dimer testing is a fast, simple, inexpensive test which can detect thrombosis in any part of the venous system.<sup>9,10</sup>

Some studies show that the expression of D-dimer in serum increases significantly in DVT; however, there are no studies on the cut-off value of D-dimers for the probability of DVT. D-dimer levels may increase if the coagulation and fibrinolysis factors are activated in the process of surgery, trauma, bleeding disorders, inflammatory diseases, kidney disorders, and pregnancy.<sup>11-13</sup>

The authors were interested in performing research on the analysis of D-dimer levels in DVT patients to determine the D-Dimer cut-off value. Accurate and fast results were expected to be obtained for the diagnosis of DVT; thus the risk of thromboembolism can be minimized, and patients who have not experienced thrombosis can get adequate anticoagulant therapy without waiting for the results of ultrasound examination.<sup>14</sup>

This study aimed to determine the diagnostic value of plasma D-dimer on Doppler ultrasound for DVT diagnosis to help clinicians to select a fast and accurate diagnostic test for the diagnosis of DVT.

## METHODS

This research was a cross-sectional study with retrospective data collection. The study was performed at the Medical Record Installation of Dr. Wahidin Sudirohusodo Hospital by taking patient data with a diagnosis of DVT from January to December 2018. The study population was all patients with a diagnosis of DVT obtained using the ICD X code from medical record data at Dr. Wahidin Sudirohusodo Hospital Makassar. The study sample included all patients with a diagnosis of DVT in addition to the results of the D-dimer measurement at Dr. Wahidin Sudirohusodo Hospital Makassar from January to December 2018. Inclusion criteria were

patients with a diagnosis of DVT in addition to the results of Wells scores, Doppler ultrasound, and D-dimer test. The D-dimer levels were measured using a device with the immunoturbidimetric method and a reference value  $<0.5 \mu\text{g/mL}$ . Patients with medical record data who did not meet the inclusion criteria and the final diagnosis, not DVT, were excluded. Data were analyzed using SPSS version 22. The t-independent test was used for normally distributed data, and the kappa test was used to assess the compatibility of D-dimers with two different tests such as Wells and Doppler ultrasound scores. The p-value  $<0.05$  was considered significant. Diagnostic tests were performed to determine the sensitivity, specificity, positive predictive value, and negative predictive value.

This research was approved by the Health Research Ethics Committee of the Faculty of Medicine, Hasanuddin University, with number 416/UN4.6.4.5.31/PP36/2019.

## RESULTS AND DISCUSSIONS

A total of 86 samples were obtained after data collection from January to December 2018. Thirty-three samples were involved as research subjects according to inclusion criteria, and 53 samples were excluded. The age of subjects was between 18-73 years with a mean of  $52.1 \pm 13.0$  years.

T-independent test (Table 1) showed insignificantly higher D-dimer mean and Wells score in positive Doppler than negative Doppler ultrasound. Receiver Operating Characteristics Curve (ROC) analysis was performed to determine the D-dimer cut-off value and Wells score, as shown in Figure 1.

The value of D-dimer Area Under Curve (AUC) was 0.784 (78.4%) or  $\geq 70\%$  that the D-dimer could be used in diagnosing DVT. The AUC of Wells score was 0.645 (64.5%) or  $\leq 70\%$ , indicating that the Wells score had a low ability to diagnose DVT.<sup>15</sup> Based on the ROC curve coordinates, which provided high sensitivity values, the cut-off D-dimer value of 2.0 was obtained. A conformity analysis was used to determine the relationship between the increase of D-dimer level and the increase of Wells score in a positive Doppler

**Table 1.** Mean of D-dimer dan Wells score based on Doppler ultrasound

Variable	Doppler Ultrasound (n=33)		p-value
	Positive (n=27)	Negative (n=6)	
D-dimer (mean, (SD))	5.29 (5.06)	2.31(1.28)	0.167
Wells score (mean; (SD))	4.74 (4.17)	4.7(1.33)	0.220

\* T-independent test was used

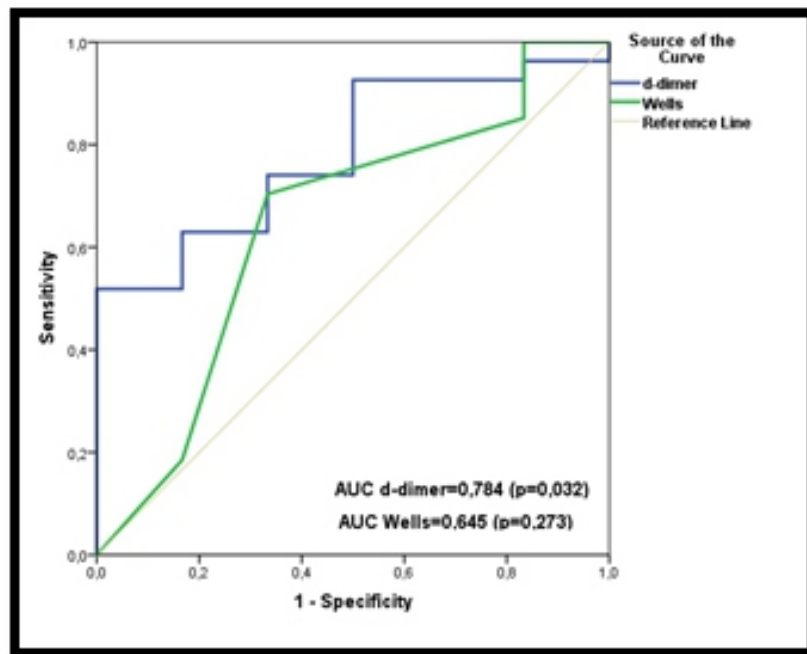


Figure 1. Analysis of ROC curve

Table 2. Compatibility between D-dimer and Doppler ultrasound

Cut-off	Doppler Ultrasound (n=33)		p-value
	Positive (n=27)	Negative (n=6)	
D-dimer $\geq 2$	25	4	0.078
D-dimer $\leq 2$	2	2	

\* Kappa test was used

Table 3. Compatibility between Wells score and Doppler ultrasound

Cut-off	Doppler Ultrasound (n=33)		p-value
	Positive (n=27)	Negative (n=6)	
Wells score $\geq 4.5$	19	2	0.088
Wells score $\leq 4.5$	8	4	

\* Kappa test was used

ultrasound and the diagnostic value of D-dimer to Doppler are shown in the following Table 2 and Table 3.

Kappa test results showed p-value  $>0.05$ , suggesting no significant correlation between D-dimer and Doppler ultrasound results. As for the diagnostic value, the following results were obtained: sensitivity of 92.6%, the specificity of 33.3%, positive predictive value of 86.2%, negative predictive value of 50.0%, accuracy of 81.8%.

Kappa test results showed p-value  $>0.05$ , suggesting no significant relationship between Wells scores and Doppler ultrasound.

As for the diagnostic value, the following results were obtained: sensitivity of 70.4%, a specificity of

66.7%, positive predictive value of 90.5%, negative predictive value of 33.3%, accuracy of 69.7%.

Diagnostic test results such as sensitivity, specificity, positive predictive value, and negative predictive value of D-dimer levels in this study were consistent with a study by Junxun Li *et al.* which found that the sensitivity of D dimer levels was higher than the specificity.<sup>16</sup> These results indicated that the measurement of plasma D-dimer levels to Doppler ultrasound could be used as a screening test. Thirty-three samples met the inclusion criteria from January to December 2018.

Analysis with the t-independent test showed insignificantly higher mean of D-dimer levels on positive Doppler ultrasound compared to negative

Doppler ultrasound. This finding was because D-dimer levels were influenced by many factors, such as trauma, post-surgery, infection, pregnancy, eclampsia, anti-coagulant drugs, age, and atherosclerosis.<sup>11-13</sup> However, these factors were not ruled out in this study, thus affecting the results of D-dimer levels. This was one of limitations of this research.

There was no significant compatibility between the Doppler ultrasound results and Wells scores. An increase in the wells score was not always followed by a positive Doppler ultrasound, suggesting a consistent finding with the theory that Doppler ultrasound has a low sensitivity in diagnosing distal DVT. Therefore, serial or venographic ultrasound should be performed in some cases.<sup>17</sup>

There is no significant compatibility between the results of Doppler ultrasound with D-dimer levels. Increased D-dimer levels in DVT patients were not always followed by positive results of Doppler ultrasound, consistent with the theory that Doppler ultrasound has limitations in establishing a diagnosis of recurrent DVT. Limitations of techniques and lower sensitivity of Doppler ultrasound on DVT were found in the inner calf vein rather than DVT, which were found in the femoropopliteal vein.<sup>18</sup>

Based on data in this study, 92.6% sensitivity, 33.3% specificity, 86.2% positive prediction value, 50.0% negative prediction value and 81.8% accuracy were obtained. The sensitivity of 92.6% showed a good ability of the D-dimer test to Doppler ultrasound, with advantages of the D-dimer test, which is easy and more practical. Contrastingly, the specificity of 33.3% indicated that the D-dimer level had a poor ability to rule out non-DVT subjects is poor. This was consistent with the theory suggesting that elevated D-dimer levels were not able to indicate the site of the abnormality and exclude other potential etiologies.<sup>11-13</sup>

A positive predictive value of 86.2% indicated the high probability of DVT occurrence in subjects if plasma D-dimer levels  $\geq 2 \mu\text{g/mL}$ . A negative predictive value of 50.0% indicated the high probability that subjects will not experience DVT if the D-dimer level  $< 2 \mu\text{g/mL}$ .

## CONCLUSIONS AND SUGGESTIONS

Based on this research, it was concluded that the D-dimer level test could be used as a screening test to determine the possibility of DVT diagnosis more quickly and to decide whether further invasive and expensive tests, which are rarely found in medical

facility such as venography are needed. Also, D-dimer levels can be a diagnostic test with cut-off value  $> 2 \mu\text{g/mL}$ .

Further research about the role D-dimers in DVT was needed by ruling out the confounding factors which were not ruled out in this study, such as trauma, post-surgery, infection, pregnancy, eclampsia, anti-coagulant drugs, age, and atherosclerosis.

## REFERENCES

1. Setiabudy RD. Hemostasis dan trombosis. Jakarta, Balai Penerbit FKUI, 2007; 1-15.
2. Heim SW, Schectman JM, Siadat MS, Philbrick JT. D-dimer testing for deep venous thrombosis: A meta-analysis. *Clinical Chemistry* 2004; 50(7): 1136-47.
3. Stone J, Hangge P, Albadawi H, Wallace A, Shamoun F, Knutti MG, *et al.* Deep vein thrombosis: pathogenesis, diagnosis, and medical management. *Cardiovasc Diagn Ther*, 2017; 7(3): S276-S84.
4. Waheed SM, Hotwagner DT. Deep Vein Thrombosis (DVT). Treasure Island (FL), Stat Pearls Publishing, 2019; 2-3.
5. England T, Nasim A. ABC of arterial and venous disease. Leicester, Wiley, 2014; 1-3.
6. Ashar BH, Miller R, Sisson S, Hospital JH, University JH. Johns Hopkins internal medicine board review: Certification and recertification. Baltimore, Elsevier/Saunders, 2012; 170-73.
7. Modi S, Deisler R, Gozel K, Reicks P, Irwin E, Brunsvold M, *et al.* Wells criteria for DVT is a reliable clinical tool to assess the risk of deep venous thrombosis in trauma patients. *World Journal of Emergency Surgery*, 2016; 11(24): 11.
8. Goodacre S, Sampson F, Thomas S, van Beek E, Sutton A. Systematic review and meta-analysis of the diagnostic accuracy of ultrasonography for deep vein thrombosis. *BMC Med Imaging*, 2005; 5(6): 1.
9. Adam SS, Key NS, Greenberg CS. D-dimer antigen: Current concepts and future prospects. *Blood*, 2009; 113(13): 2878-87.
10. Pulivarthi S, Gurram MK. Effectiveness of d-dimer as a screening test for venous thromboembolism: An update. *N Am J Med Sci*, 2014; 6(10): 491-9.
11. Jiang Y, Li J, Liu Y, Zhang W. Diagnostic accuracy of deep vein thrombosis is increased by analysis using combined optimal cut-off values of postoperative plasma D-dimer levels. *Exp Ther Med*, 2016; 11(5): 1716-20.
12. Hasegawa M, Wada H, Yamaguchi T, Wakabayashi H, Fujimoto N, Matsumoto T, *et al.* The evaluation of D-dimer levels for the comparison of fibrinogen and fibrin units using different D-dimer kits to diagnose VTE. *Clin Appl Thromb Hemost*, 2018; 24(4): 655-62.
13. Chopra N, Doddareddy P, Grewal H, Kumar PC. An elevated D-dimer value: A burden on our patients and hospitals. *Int J Gen Med*, 2012; 5(127): 87-92.
14. Karande GY, Hedgire SS, Sanchez Y, Baliyan V, Mishra V,

- Ganguli S, *et al.* Advanced imaging in acute and chronic deep vein thrombosis. *Cardiovasc Diagn Ther*, 2016; 6(6): 493-507.
15. Safari S, Baratloo A, Elfil M, Negida A. Evidence-based emergency medicine; part 5 receiver operating curve and area under the curve. *Emerg (Tehran)*, 2016; 4(2): 111-3.
16. Li J, Zhang F, Liang C, Ye Z, Chen S, Cheng J. The diagnostic efficacy of age-adjusted D-dimer cut-off value and pretest probability scores for deep venous thrombosis. *Clin Appl Thromb Hemost*, 2019; 25: 1-7.
17. Hotoleanu C, Fodor D, Suciu O. Correlations between clinical probability and Doppler ultrasound results in the assessment of deep venous thrombosis. *Medical Ultrasonography*, 2010; 12: 17-21.
18. Needleman L, John CJ, Michael LP, Geno MJ, Adhikari S, Barbara HS, *et al.* Ultrasound for lower extremity deep venous thrombosis. *Circulation*, 2018; 137(14): 1505-15.